

6-1954

New Techniques in Ptosis Surgery

Robert A. Schimek

Follow this and additional works at: <https://scholarlycommons.henryford.com/hfhmedjournal>



Part of the [Life Sciences Commons](#), [Medical Specialties Commons](#), and the [Public Health Commons](#)

Recommended Citation

Schimek, Robert A. (1954) "New Techniques in Ptosis Surgery," *Henry Ford Hospital Medical Bulletin* : Vol. 2 : No. 2 , 89-95.

Available at: <https://scholarlycommons.henryford.com/hfhmedjournal/vol2/iss2/9>

This Article is brought to you for free and open access by Henry Ford Health System Scholarly Commons. It has been accepted for inclusion in Henry Ford Hospital Medical Journal by an authorized editor of Henry Ford Health System Scholarly Commons.

NEW TECHNIQUES IN PTOSIS SURGERY

ROBERT A. SCHIMEK, M.D.*

Ptosis, or drooping of the upper lid, may be congenital or acquired. Congenital ptosis is three times more frequent.¹ The success of an operation for congenital ptosis depends on the degree of levator function and the presence of associated defects. Developmental defects frequently found with congenital ptosis are (1) paresis of the superior rectus or other extra-ocular muscles, (2) epicanthus, (3) amblyopia, (4) jaw-winking, (5) Duane's retraction syndrome, (6) blepharophimosis, and (7) mental retardation. The presence of any of these may modify the type of surgery indicated.

Acquired ptosis may be due to neurological lesions, trauma, or diseases affecting the lids. Acquired ptosis should not be operated upon until all other treatment directed to the cause has failed, and it is apparent that there will be no spontaneous improvement in the ptosis. Paralysis of the third nerve or its nucleus, or the cervical sympathetics on one side (Horner's syndrome) should usually be present at least a year before the ptosis is considered permanent enough to warrant operation. Ptosis due to cicatrix from skin defect, trachoma, or pemphigus, or from local tumors, should be treated first by resection of the scar tissue or tumor. Later a ptosis operation may be necessary. The treatment of myasthenia gravis or progressive nuclear ophthalmoplegia is usually non-surgical, since such patients are likely to develop postoperative diplopia or exposure keratitis. Other causes of acquired ptosis which usually contra-indicate surgery are: active states of palpebral edema, trachoma, and vernal catarrh; untreated syphilitic lesions; thyrotoxicosis; hysteria; intoxications from coal tar derivatives, lead poisoning, and botulism; and acute infections such as diphtheria and influenza.

The 80 odd varieties² of ptosis operations can be divided into four groups. They are based on the principle of (1) resection of the skin, (2) use of superior rectus, (3) use of frontalis muscle, or (4) enhanced use of the levator.

Skin excision methods may be dismissed as not being permanent or practical, except in cases of blepharochalasis. Use of the superior rectus is permissible for bilateral ptosis with normal superior rectus action. However, this type operation carries with it some danger of exposure keratitis, from interference with normal blinking and incomplete lid closure during sleep. In addition, other complications which may occur include diplopia and hypotropia, arching of the lid margin, entropion and trichiasis, and excessive postoperative scarring.

Frontalis motion can be transmitted to the tarsal border of the lid by permanent sutures, temporary sutures forming scar tracts, flaps of skin or fascia lata, and muscle strips of orbicularis or of frontalis. This type of operation gives the lid voluntary movement in the absence of levator function. The disadvantages are the peculiar facial expression which may result from use of the frontalis, the lack of

*Associate Surgeon, Department of Ophthalmology.

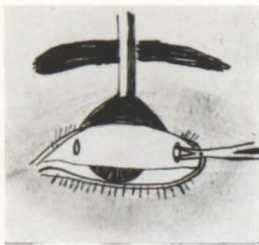


Fig. 1—The upper lid is everted with a lid holder. With sharp-pointed scissors a buttonhole is made medially and laterally through conjunctiva and levator tissue above the tarsal plate.

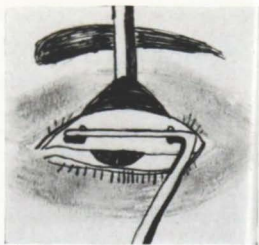


Fig. 2—One jaw of a Berke ptosis clamp is then passed into the temporal buttonhole, passed across the lid beneath conjunctiva and levator, and out through the nasal buttonhole. The jaws are clamped together.

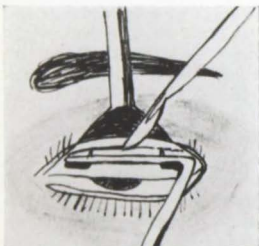


Fig. 3—An incision is made between the clamp and the border of the tarsus through conjunctiva and levator.

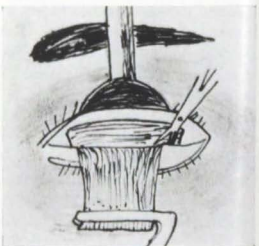


Fig. 4—By sharp and blunt dissection, the levator, Mueller's muscle, and the conjunctiva are separated as one layer from the septum orbitale, to the level of the upper fornix.

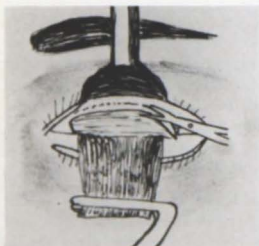

Fig. 5—A 2 or 3 mm. tarsectomy is performed.

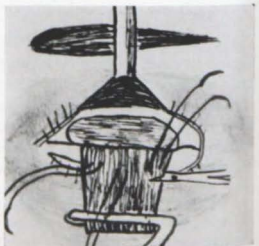

Fig. 6—3 double arm sutures are then passed through the layer of conjunctiva, Mueller's muscle and levator about 12 mm. to 15 mm. from the free border. Excision is performed 2 to 3 mm. in front of the suture line.

complete synchronization of movement between the lid and the eye when the eye is rotated vertically, and danger of exposure keratitis during the early postoperative period.

Operations which enhance levator action (as in levator resection) have the great advantage of producing normal blinking and synchronous following movements of the lid with the eye. There is a relatively small incidence of excessive post-operative scarring, lagophthalmos, deformation of the lid margins, diplopia induced by operation, or unsightly asymmetrical elevation of the brow. With levator action present, levator resection gives the most ideal results. However, if there is no levator action, poor lid mobility may result.

The original Blaskovics technique of levator resection has the disadvantage of requiring tedious dissection of the conjunctiva and the levator from the other lid structures. Also the conjunctiva may be buttonholed and Mueller's muscle may be accidentally reflected with conjunctiva. Annoying bleeding is usually present during the dissection. A modification of the Blaskovics operation which has been used by Guyton⁵ since 1946 has the advantage of quickness, simplicity, and preservation of the normal relationships of the levator, Mueller's muscle and conjunctiva to the septum orbitale. Bleeding is minimal because of the minimum dissection required. What dissection is done lies between natural tissue planes, as between levator and septum orbitale. The technique is as follows: The lid is everted. A horizontal incision is made through conjunctiva and tarsus parallel to and a few mm. from the superior tarsal border. The tarsal rim with its vessels can be clamped by a Kelly clamp or a Berke lid clamp. The rim of tarsus with the attached levator, Mueller's muscle, and conjunctiva is separated from the lid well up into the superior fornix. This tongue of levator (with its attached tarsal rim and conjunctiva) is resected and the stump is reattached to the resected tarsus.

Iliff⁴ uses a procedure similar to this, grasping the levator and conjunctiva with the Berke lid clamp. This modified Blaskovics technique is described in figures 1-9.

Figure 10 is an example of a bilateral case of ptosis, which was more marked on the left side, with fair levator action on both sides. The levator on the right was resected by the original Blaskovics technique and the levator on the left was resected by the modified technique used by Guyton and Iliff. Although the same amount of levator tissue was resected in each eye, the modified technique (performed on the more ptosed left eye) resulted in a greater correction than the Blascowicz technique. Theoretically this could be expected because of maintenance of normal relations between the shortened levator muscle, Mueller's muscle, and the shortened conjunctiva with the modified technique. There has been no complication from excessive shortening of the conjunctiva in any of the cases done with the modified technique.

Many authors agree that levator function must be present preoperatively, or levator resection will give inadequate correction, or at best, correction with poor lid mobility. However, de Blaskovics⁵ stated that "even when the muscle is absent—an apparent function develops even in those cases in which this muscle

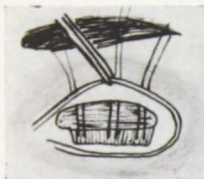


Fig. 7—The lid retractor is then removed and the upper tarsus is everted with forceps. The 3 double arm sutures are passed through the upper tarsal border and brought out about 2 mm. from the lash border.

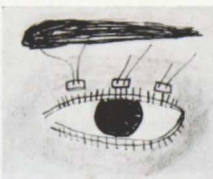


Fig. 8—These are tied over pegs or over a long thin rubber peg.




Fig. 9—Two Frost sutures are then placed from the lower lid to the brow to protect the cornea. A modified pressure dressing is applied.

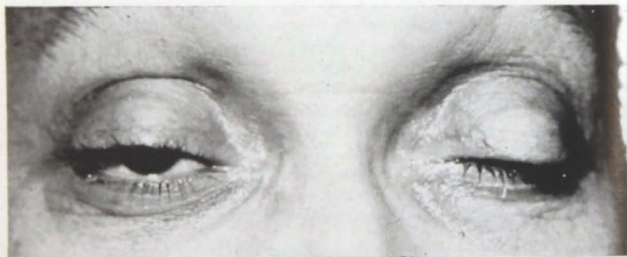

Fig. 10—Preoperative appearance of bilateral ptosis, more marked left eye, with fair levator function O. U.

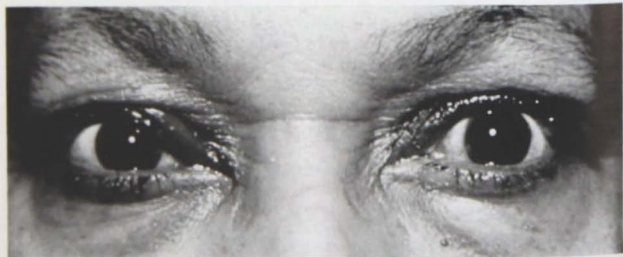

Fig. 11—Postoperative appearance with Blaskovics performed on the right and the modified Blaskovics technique on the more severely drooping left upper lid. The same amount of levator was resected in each eye, but the modified technique was more effective.



Fig. 12—Combined levator shortening and frontalis operation: Levator and conjunctiva are isolated on a Berke ptosis clamp exactly as in the modified Blaskovics technique. (as shown in figures 1-4) If a fairly sturdy piece of levator has been obtained, the conjunctiva should be peeled off from the distal 12 mm. of the levator tendon where it will be buried in the lid. This can easily be done with scissors by blunt dissection.



Fig. 13—The levator is split longitudinally and a double armed mattress suture passed through each end.

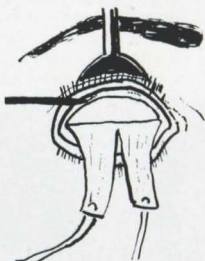

Fig. 14—With the lid everted on a retractor, small incisions are made with a knife in the tarsus just below and parallel to the superior tarsal border in the medial and lateral halves of the tarsal plate.



Fig. 15—Small horizontal incisions are made medially and laterally above the brow as in the Reese type operation. A ptosis knife is passed through each brow incision and down through the corresponding tarsal plate buttonhole. The sutures from each tongue of levator are passed through the hole in the blade of the ptosis knife.

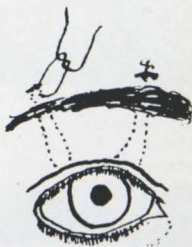


Fig. 16—With the ptosis knife, each longitudinal band of levator is pulled through the buttonhole in the tarsus, up to the frontalis muscle, and out of the corresponding brow incision. The levator is sutured to the frontalis muscle through the incisions above the eye brow. These incisions are sutured. The lower lid should be pulled up to protect the cornea by Frost sutures as in Figure 9.

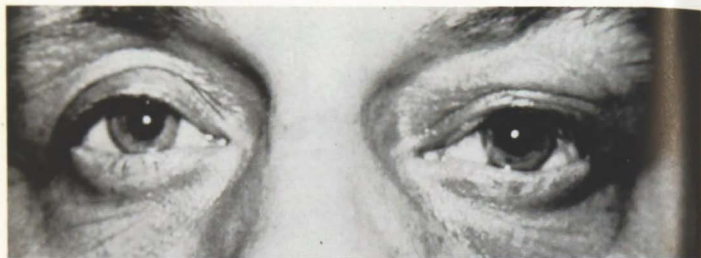

Fig. 17—Result of combined levator resection-frontalis operation, left eye. Eyes in primary position. Two weeks postoperative.

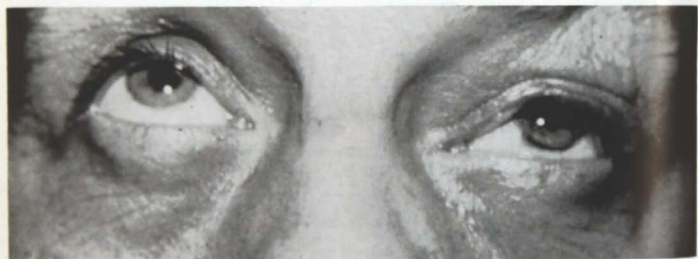

Fig. 18—Good lid movement on upward gaze with levator and frontalis action.

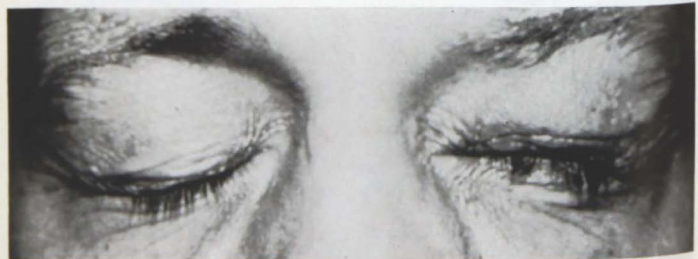

Fig. 19—Satisfactory lid closure.

is completely paralyzed or atrophic." Many others, such as Lindner and Jaensch, agree with this.

In cases without any levator function preoperatively, it should be advantageous to combine shortening of the levator with a frontalis type operation. One would like to enhance levator function to the maximum degree and still obtain accessory frontalis action. This accessory frontalis action can compensate for any under correction or lack of mobility of the lid that might result from doing a simple levator resection in a case with complete paralysis. Techniques combining shortening of the levator with a frontalis type operation have been described by Wilder⁶ and Beard.⁷

The new operative procedure to be described herein exactly follows the modified Blaskovics technique for the stages up to the isolation and dissection of the levator muscle. (Figures 1 to 4.) Figures 12 to 16 show the subsequent stages. The levator tendon and muscle are split longitudinally into two portions. Two horizontal incisions are made through the tarsus just below its superior border. Each tarsal incision or "buttonhole" must be several millimeters from the center of the lid to avoid subsequent arching of the lid margin. Two skin incisions are made above the brow as in the Reese operation. Each tongue of levator is pulled through its tarsal buttonhole and up through the lid to the corresponding brow incision. The levator is sutured to the frontalis through the two incisions above the brow. Thus an effective sling of levator muscle and tendon is looped through the upper tarsus and is attached to the frontalis. The result gives the advantages of shortening the levator muscle and also allows use of the frontalis muscle as an auxiliary voluntary means of moving the lid.

Figures 16 to 18 show the postoperative result of a combined levator resection and utilization of frontalis type operation. It is of interest that this patient had two previous unsuccessful ptosis operations: A resection of the tarsus by the Everbusch technique had failed, and Friedenwald-Guyton suture also failed when the tantalum wire broke.

In summary, a modification of the Blaskovics procedure is recommended because of its technical simplicity, shorter operative time, and equal or slightly greater effectiveness. A new operation combining levator shortening with frontalis utilization is described for those cases of ptosis without any apparent levator function.

BIBLIOGRAPHY

1. Report of the Moorfield's Hospital, London, 1932.
2. Berke, R. N.: Blepharoptosis, *Arch. Ophth.* 34:434, 1945.
3. Guyton, J. S.: Personal communication.
4. Iliff, C. E.: Wilmer Ophthalmological Institute meetings, April, 1953.
5. De Blaskovics, L.: Treatment of ptosis; formation of a fold in the eyelid and resection of the levator and tarsus, *Arch. Ophth.* 1:672, 1929.
6. Wilder, W. H.: Operation for ptosis, *Tr. Am. Ophth. Soc.* 8:92, 1897-1899.
7. Beard, C. H.: *Ophthalmic surgery*, 2d ed., Philadelphia, P. Blakiston's Son & Co., 1914, pp. 230-252.